

10. Directed Cardiac Physical Exam

- A. **The History and Physical are not yet dead** in clinical medicine. However, much of the classically taught physical exam such as jugular pulse forms and apical pulse forms are difficult, time consuming and not clinically useful. Auscultation is useful even if you are not very good at what you are doing!
- B. **Be technologically friendly.** Future internist and Emergency Physicians will probably use an ultrasound probe in most of the physical exam. Today, If you think there is a pulmonic effusion “get the ultrasound probe” and if you hear a murmur which does not sound benign “get an echocardiogram”. Admittedly, a directed physical can only occasionally give data not gleaned from a good history. Yet, a directed physical should take only a few minutes.

- C. **Vitals:** BP, P, O₂ Sat, RR, Wt, Ht (BSA).
Tilts if indicated.

D. Neck

1. Jugular venous distention, (nl-12 cm)
2. Hepatojugular reflux.
3. Carotid Bruits

E. Chest

1. External Appearance
 - a. Anteroposterior diameter
 - b. Symmetry/movement, accessory muscles
2. Auscultation
 - a. Air movement
 - b. Rales, rhonchi, wheezes, stridor, rubs

F. Cardiac

1. Location of apical impulse, amplitude
2. Auscultation
 - a. Murmurs: first listen for systolic murmurs, then diastolic (usually quieter)
 - b. Gallops: S4-(Tennessee), S3-(Kentucky) suspect in systolic CHF and MR.
 - c. Clicks
 - d. Attempt to characterize splitting of S2.

G. Abdomen

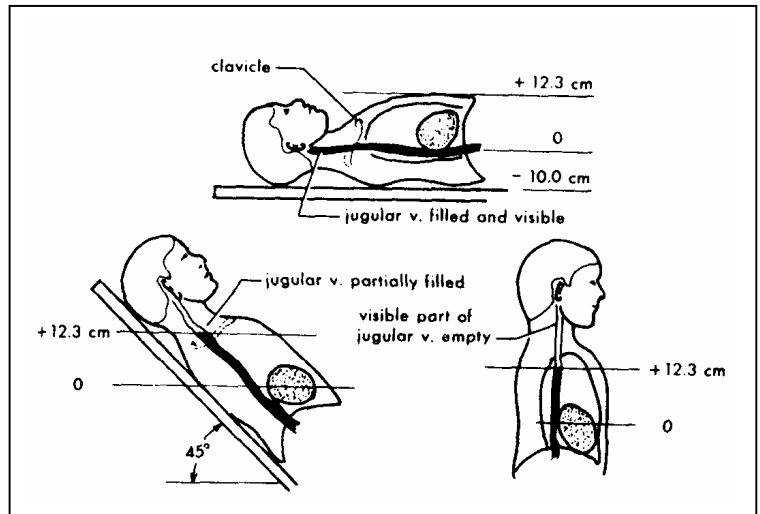
1. Shape, contour, visible aorta pulsations
2. Bowel Sounds
3. Palpation findings
4. Percussion findings (Liver - total span)

H. Extremities

1. General: Temperature, color, hair distribution
2. Particular attention to lower extremities: skin texture, nails, veins
3. Evaluation of Thrombosis (Tenderness, Erythema, Cord, Homans' sign)
4. Pulses: (Symmetry)
5. Peripheral edema
6. Femoral bruits

I. Neurological Exam

1. Detail exam not needed if patient is good historian and is walking.



NAMES

1. **PULSUS PARVUS** (Weak pulse) low output failure
2. **PULSUS TARDUS** (Anacrotic pulse): Aortic stenosis (AS).
3. **PULSUS BISFERIENS** (Bifid pulse): Aortic insufficiency (AI).
4. **PULSES ALTERNANS**: With severe L-heart failure.
5. **PULSUS PARADOXUS**: SBP > 10 mm Hg with inspiration. Tamponade
6. **WATERHAMMER PULSE**: Wide pulse pressure. AI
7. **SPIKE AND DOME PULSE**: Double systolic peaks. HCM outflow obst.
8. **DICROTIC PULSE**: 2 (systole/diastole).-Myocardial disease hypovolemic
9. **BIGEMINAL PULSE**: Alternating normal and PVC's PAC'S.